

Blood parasitism by hemogregarines in Central European lizards

Unicellular blood parasites of the apicomplexan suborder Adeleorina, collectively known as hemogregarines, are common, widely distributed, and speciose pathogens of all reptilian orders (TELFORD 2008). Lacertidae are specifically infected by members of the genera *Haemogregarina*, *Hepatozoon* and *Karyolysus*, which use the blood cells of their hosts for maturing to gamonts. Among these pathogens, *Karyolysus* seems to be a prevalent parasite in Palearctic lizards. Even population decline in the Sand Lizard, *Lacerta agilis* LINNAEUS, 1758, was attributed to this hemogregarine (SVAHN 1974). In spite of the infection's presumed significance as a major ecological factor, epidemiological and taxonomic data on lizard hemogregarines in Central Europe are scarce and scattered.

From Middle Europe, only four hemogregarine species living in lacertid blood cells have been reported, provided that only such records were considered, which pres-

Table 1: Hemogregarine species in the blood of Middle European lacertids. Data compiled from SVAHN (1974), MIHALCA et al. (2008), TELFORD (2008) and MAJLÁTHOVÁ et al. (2010). * - Problematic information, since the lizard species is not known to occur in this country.

Lacertid taxon	Hemogregarine taxon	Countries of study and/or record
<i>Lacerta agilis</i> LINNAEUS, 1758	<i>Karyolysus lacazei</i> (LABBÉ, 1894)	Denmark, France, Sweden
	<i>Karyolysus lacertae</i> (DANILEWSKY, 1886)	Denmark, Romania, Ukraine
	(syn. <i>K. lacertarum</i>)	
	<i>Karyolysus latus</i> SVAHN, 1975	Denmark, Sweden
	<i>Karyolysus minor</i> SVAHN, 1975	Denmark, Sweden
<i>Lacerta viridis</i> (LAURENTI, 1768)	<i>Karyolysus</i> sp.	Poland
	<i>Sauroplasma boreale</i> SVAHN, 1976	Denmark, Sweden
	<i>K. lacazei</i>	Denmark*
<i>Podarcis muralis</i> (LAURENTI, 1768)	<i>K. lacertae</i>	France*, Ukraine
	<i>K. lacazei</i>	Switzerland, Denmark*, Sweden*
<i>Podarcis tauricus</i> (PALLAS, 1814)	<i>K. lacertae</i>	France, Ukraine*
<i>Podarcis siculus</i> (RAFINESQUE-SCHMALTZ, 1810)	<i>K. lacertae</i>	Ukraine
		France
<i>Zootoca vivipara</i> (JACQUIN, 1787)	<i>K. lacazei</i>	Denmark
	<i>K. lacertae</i>	Denmark, France, Russia
	<i>K. latus</i>	Denmark, Sweden
	<i>Karyolysus</i> sp.	Poland

ent information about the parasite's identity, the host taxon and the record locality (Table 1).

All these hemogregarine species are members of the genus *Karyolysus*. It seems to be proven by experimental infections that, in the genus *Karyolysus*, sporogony occurs within adult mites of the parasitic species *Ophionyssus saurarum* (OUDEMANS, 1901) (syn: *Sauronyssus*, *Liponyssus*), and that infection of the lizard can only take place by ingestion of nymphs of the subse-

quent mite generation. *Ophionyssus saurarum* is, however, an erratic parasite of lizards (AMO et al. 2005; GWIAZDOWICZ & FILIP 2009), and typically various *Ophionyssus* species compete within one habitat, and in the author's opinion, the infection route suggested (ingestion of mite nymphs) appears to be rather ineffective in the wild. Thus, hemogregarines detected by chance within red blood cells of heavily tick-infested lizards were tentatively attributed to the tick-borne genus *Hepatozoon* (HASSL 2003).

Table 2: Hemogregarines and ticks parasitizing Central European lizards, as observed in the author's study. m/f/juv - male/female/juvenile lizards studied; N - Northern latitude; E - Eastern longitude; No. - number of; l/w - length to width ratio; Ø - average.

Host species	m/f/juv	Materials lizards	Date	N	E	Altitude	Location [m a.s.l.]
<i>Algyroides nigropunctatus</i> (DUMÉRIE & BIBRON, 1839)	1/0/0	blood smear	May 2002	45°06'	14°21'	120	Croatia
	1/0/0	ticks	May 2002	44°59'	14°28'	47	Croatia
<i>Iberolacerta horvathi</i> (MÉHELY, 1904)	1/1/0	blood smear	June 1999	46°36'	13°13'	1250	Carinthia
	5/1/1	ticks	June 1999	46°36'	13°13'	1250	Carinthia
<i>Lacerta agilis</i> LINNAEUS, 1758	0/0/1	blood smear	June 2009	46°30'	19°30'	-	Hungary
	2/1/1	ticks	June 2000	47°44'	15°03'	650	Lower Austria
<i>Lacerta bilineata</i> DAUDIN, 1802	3/0/0	blood smear	May 2002	45°06'	14°21'	120	Croatia
	1/0/0	ticks	May 2002	45°06'	14°21'	120	Croatia
<i>Podarcis muralis</i> (LAURENTI, 1768)	0/0/1	blood smear	May 2002	45°06'	14°21'	120	Croatia
	1/0/1	ticks	May 2002	45°06'	14°21'	120	Croatia
<i>Podarcis melisellensis</i> (BRAUN, 1877)	2/2/0	blood smear	May 2002	45°06'	14°21'	120	Croatia
	3/3/0	ticks	May 2002	45°06'	14°21'	120	Croatia
<i>Zootoca vivipara</i> (JACQUIN, 1787)	0/1/0	blood smear	June 1999	46°36'	13°08'	1360	Carinthia
	1/1/0	blood smear	June 2000	47°45'	15°50'	1100	Lower Austria
	0/1/0	blood smear	June 2000	47°51'	15°16'	722	Lower Austria

Below, this classification is reevaluated and more epidemiological information is added.

During the author's tick collecting excursions, thin blood smears were prepared either from blood drops emerging during tick removal or from carcasses of lizards killed most recently by accidents. Smears were fixed in methanol and stained according to the standard Giemsa procedure in a Weise's buffer solution (pH = 7.2) (CHEESBROUGH 1987). The hemoparasitic species were categorized using the identification key given by TELFORD (2008).

As disclosed in Table 2, the author found three more lacertid host species of *Karyolysus latus*, viz. *Algyroides nigropunctatus* (DUMÉRIL & BIBRON, 1839), *Podarcis muralis* (LAURENTI, 1768), and *P. melisellensis* (BRAUN, 1877). Moreover, a Carinthian *Iberolacerta horvathi* (MÉHELY, 1904) was also parasitized by *Karyolysus*. Unfortunately a reliable species determination of the parasite was impossible, as the single parasite detected did not unequivocally fit the characteristics given by TELFORD (2008). In the *Karyolysus* form found in *I. horvathi*, the ratio of length to width (l/w) was 1.9; the hemogregarine species coming closest in size was *K. latus*, but its l/w ratio is 2.15. The mentioned identification key is based on cell size and area ratios. However, within tinctorially processed blood smears, the cell dimensions of an

intraerythrocytic parasite depend on the erythrocyte size and deformability (KROGSTAD et al. 1991). ARÝKAN et al. (2009) reported the size of *P. muralis* red blood cells to be 11.8-16.3 µm in length, and 7.0-9.5 µm in width, with an l/w ratio of 1.47-1.96, which differs from our results (13.6-15.9 µm, 9.1-10.4 µm, and l/w ratio: 1.31-1.53; $n = 10$). This obvious difference could be the consequence of different blood preparation techniques. If so, the capture of size and area extensions of the gamonts without considering ratios and coloration factors may indeed constitute insufficient criteria for the differentiation of hemogregarine taxa, leading to inaccurate results rather than the evaluator's incompetence to discriminate the parasites' developmental stages, as has been postulated by ROCA & GALDON (2010). Nevertheless, a molecular biological species differentiation has not been established yet, apart from a phylogenetic study on unnamed *Hepatozoon* taxa from North African lizards (MAIA et al. 2011).

Croatia is a newly recognized country to house *K. latus*, and Lower Austria has to be added to the list of areas where *K. lacertae* occurs (Table 2). *Karyolysus lacertae* is the only European species known to produce encapsulated gamonts which are thus resistant to stain penetration, to some degree (Fig. 1). The Croatian finding closes the gap between the known localities of *K. lacertae* infections of *Z. vivipara* lizards in Denmark

Table 2 (continued from opposite page): Hemogregarines and ticks parasitizing Central European lizards, as observed in the author's study. m/f/juv - male/female/juvenile lizards studied; N - Northern latitude; E - Eastern longitude; No. - number of; l/w - length to width ratio; Ø - average.

No. parasites / No. hosts	Hemogregarina size in µm	Erythrocyt size in µm
1 <i>Karyolysus latus</i> / 1 lizard	-	-
1 nymph of <i>Haemaphysalis concinna</i> / 1 lizard		
1 <i>Karyolysus</i> sp. / 2 lizards	10.3 x 5.4; l/w = 1.9	14.1-15.5 x 7.1-8.5
10 nymphs of <i>Ixodes</i> sp. / 7 lizards		
0 / 1 lizard		
6 larvae, 17 nymphs of <i>Ixodes ricinus</i> / 4 lizards		
0 / 3 lizards		
0 / 1 lizard		
1 <i>Karyolysus latus</i> / 1 lizard	11.5 x 5.3; l/w = 2.17	13.6-15.9 x 9.1-10.4
8 nymphs of <i>Haemaphysalis concinna</i> / 1 lizard		
3 <i>Karyolysus latus</i> / 4 lizards	11.4-16.0 x 6.4; l/w Ø = 2.15	13.6-16.0 x 7.7-10.0
4 nymphs of <i>Haemaphysalis concinna</i> / 2 lizards		
0 / 1 lizard		
0 / 2 lizards		
1 <i>Karyolysus lacertae</i> / 1 lizard	10.4x3.6; l/w = 2.8	-

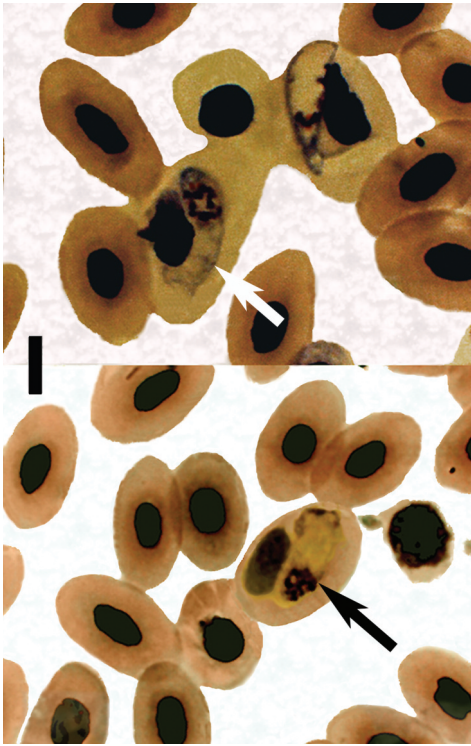


Fig. 1: above: *Karyolysus latus* SVAHN, 1975, from Croatian *Podarcis muralis* (LAURENTI, 1768); below: *Karyolysus lacertae* (DANILEWSKY, 1886) from Lower Austrian *Zootoca vivipara* (JACQUIN, 1787). Note that this parasite is resistant to stain penetration. Bar represents 10 μ m.

and France in the West and Ukraine and Russia in the East.

Although most Palearctic *Karyolysus* species completed their life-cycles in *Ophionyssus* mites in the laboratory (TELFORD 2008), the effectiveness of the postulated life-cycle in the wild is dubious. Transmission of a blood parasite by the bite of an infectious tick appears to be much more efficient than ingestion of mite nymphs; and ticks stuck to lizards are much more abundant in nature than molesting mite nymphs (MAJLATHOVA 2010). Also, in the present study, only ticks but no mite nymphs were found parasitizing the lizards (Table 2). Whether *Karyolysus* can complete its life-cycle not only in the mite *O. saurarum* but also in local tick species, is unknown. Thus,

one can hypothesize an association of some Palearctic *Karyolysus* species with ticks, especially of *K. latus* with the Mediterranean rodent tick, *Haemaphysalis concinna* KOCH, 1844 (HASSL 2003), as more than 90 % of the lizards infected with *Karyolysus* were found to be infested with ticks.

REFERENCES: AMO, L. & LOPEZ, P. & MARTIN, J. (2005): Prevalence and intensity of haemogregarine blood parasites and their mite vectors in the common wall lizard, *Podarcis muralis*. - Parasitology Research, Heidelberg; 96: 378-381. ARÝKAN, H. & GÖCMEN, B. & YILDIZ, M. Z. & ILGAZ, Ç. & KUMLUTAŞ, Y. (2009): Morphology of peripheral blood cells from some lacertid lizards from Turkey. - Russian Journal of Herpetology, Moskva; 16 (2): 101-106. CHEESBROUGH, M. (1987): Medical laboratory manual for tropical countries. Volume I; London Boston Durban, Singapore, Sydney, Toronto, Wellington (Butterworths), pp. 605. GWIAZDOWICZ, D. J. & FILIP, K. P. (2009): *Ophionyssus saurarum* (Acari, Mesostigmata) infecting *Lacerta agilis* (Reptilia, Lacertidae). - Wiadomosci Parazytologiczne, Warszawa; 55 (1): 61-62. HASSL, A. R. (2003): Ectoparasite of lizards and possible vector: the mammal hard tick *Haemaphysalis concinna* KOCH, 1844. - Herpetozoa, Wien; 16 (1/2): 86-88. KROGSTAD, D. J. & SUTERA, S. P. & BOYLAN, C. W. & GLUZMAN, I. Y. & QIAN, Z. F. & RAO, P. R. (1991): Intraerythrocytic parasites and red cell deformability: *Plasmodium berghei* and *Babesia microti*. - Blood Cells, Amsterdam; 17 (1): 209-21. MAIA, J. P. M. C. & HARRIS, D. J. & PERERA, A. (2011): Molecular survey of *Hepatozoon* species in lizards from North Africa. - Journal of Parasitology, Lawrence; 97 (3): 513-517. MAJLATHOVÁ, V. & MAJLÁTH, I. & HAKLOVÁ, B. & HROMADA, M. & EKNER, A. & ANTICZAK, M. & TRYJANOWSKI, P. (2010): Blood parasites in two co-existing species of lizards (*Zootoca vivipara* and *Lacerta agilis*). - Parasitology Research, Heidelberg; 107: 1121-1127. MIHALCA, A. D. & RACKA, K. & GHERMAN, C. & IONESCU, D. T. (2008): Prevalence and intensity of blood apicomplexan infections in reptiles from Romania. - Parasitology Research, Heidelberg; 102: 1081-1083. ROCA, V. & GALDÓN, M. A. (2010): Haemogregarine blood parasites in the lizards *Podarcis bocagei* (SEOANE) and *P. carbonelli* (PÉREZ-MELLADO) (Sauria: Lacertidae) from NW Portugal. - Systematic Parasitology, Vienna, New York; 75: 75-79. SVAHN, K. (1974): Incidence of blood parasites of the genus *Karyolysus* (Coccidia) in Scandinavian lizards. - Oikos, København; 25 (1): 43-53. TELFORD, S. R. (2008): Hemoparasites of the Reptilia. Color atlas and text; Boca Raton (CRC Press), pp. 376.

KEY WORDS: Reptilia: Squamata: Sauria: Lacertidae; Apicomplexa, Adeleorina, *Haemogregarina*, *Hepatozoon*, *Karyolysus lacazei*, *K. lacertae*, *K. latus*, *K. minor*; blood parasite, Central Europe

SUBMITTED: January 11, 2012

AUTHOR: Andreas R. HASSL, Department of Specific Prophylaxis and Tropical Medicine, Center for Pathophysiology, Infectiology & Immunology, Kinderspitalgasse 15, A-1090 Vienna; Austria < andreas.hassl@meduniwien.ac.at >